

LUNG PERFUSION STUDY

(Tc-99m-Macroaggregated Albumin)

Overview

- The lungs have a dual blood supply via the pulmonary and bronchial arteries. The Lung Perfusion Study demonstrates the distribution of lung perfusion via the pulmonary arteries in multiple projections.

Indications

- Diagnosis of pulmonary embolism, particularly when helical CT is contraindicated because of renal insufficiency or a history of a bona fide contrast reaction (1-5).
- Evaluation of regional pulmonary perfusion prior to lung reduction surgery (6,7).

Examination Time

- 45 minutes.

Patient Preparation

- None.

Equipment & Energy Windows

- Gamma camera: Large field of view, preferably a dual head camera.
- Collimator: Low energy, high resolution, parallel hole.
- Energy window: 20% window centered at 140 keV.

Radiopharmaceutical, Dose, & Technique of Administration

- Radiopharmaceutical: Tc-99m-macroaggregated albumin.
- Dose:
 - 6 mCi (222 MBq) - if performed in conjunction with a gas ventilation study.
 - 2 mCi (37-74 MBq) - if performed before a Tc-99m-DTPA aerosol study.
- Technique of administration: Standard intravenous injection.

Patient Position & Imaging Field

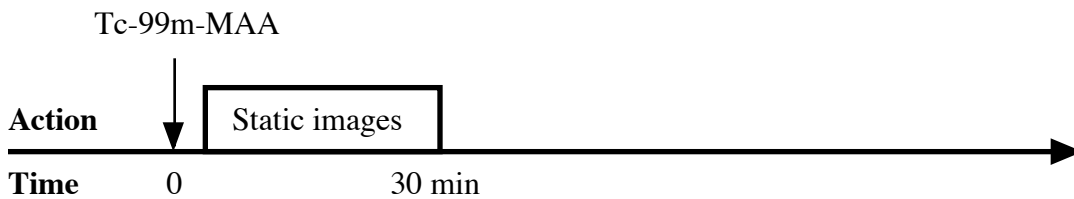
- Patient position: Sitting (supine if unable to sit).
- Imaging field: Entire lungs.

Acquisition Protocol

- Imaging may begin immediately.

- Acquire images in the POST, LPO, L LAT, ANT, R LAT, and RPO projections. (If a dual head camera is used, acquire RAO and LAO projections as well.)
 1. Acquire each image for approximately 500 K.
- ☐ SPECT images of perfusion and ventilation may be substituted for planar imaging (5).
- Always compare the results to a chest radiograph(s) obtained within the last 24 hours.

Protocol Summary Diagram



Data Processing

- None.

Optional Maneuvers

- Quantitation: Unilateral or regional pulmonary function may be quantitated (7,8).
- Secondary xenon-133 ventilation studies: Xenon-133 gas ventilation studies may be done after the Tc-99m-MAA perfusion study, either as a reventilation study to obtain ventilation information in an additional view or as the sole ventilation study. If this approach is planned or likely, the dose for the perfusion study may be reduced (9,10).
- Functional images: Images of perfusion and ventilation information combined may be generated (11).

Principle Radiation Emission Data - Tc-99m (12)

- Physical half-life = 6.01 hours.

Radiation	Mean % per disintegration	Mean energy (keV)
Gamma-2	89.07	140.5

Dosimetry - Tc-99m-Macroaggregated Albumin (13)

Organ	rads/6 mCi	mGy/222 MBq
Lungs	1.32	13.2
Bladder wall		
2 hour void	0.18	1.8
4.8 hour void	0.33	3.3
Liver	0.11	1.1
Spleen	0.10	1.0
Total body	0.09	0.9
Kidneys	0.066	0.66
Ovaries		
2 hour void	0.045	0.45
4.8 hour void	0.051	0.51
Testes		
2 hour void	0.036	0.36
4.8 hour void	0.039	0.39

References

1. Winer-Muram, et al: Pulmonary embolism in pregnant patients: Fetal radiation dose with helical CT. Radiology 224:487-492, 2002.
2. Klingensmith WC, Holt SA: Lung scan interpretation: A user-friendly, physiologic approach. J Nucl Med 33:1417-1422, 1992.
3. Parker JA, Coleman RE, Siegel BA, et al: Procedure guideline for lung scintigraphy: 1.0. J Nucl Med 37:1906-1910, 1996.
4. Coche E, Verschuren F, Keyeux A, et al: Diagnosis of acute pulmonary embolism in outpatients: Comparison of thin-collimation multi-detector row spiral cT and planar ventilation-perfusion scintigraphy. Radiology 229:757-765, 2003.
5. Reinartz P, Wildberger JE, Schaefer W, et al: Tomographic imaging in the diagnosis of pulmonary embolism: A comparison between V/Q lung scintigraphy in SPECT technique and multislice spiral CT. J Nucl Med 45:1501-1508, 2004.
6. Wang SC, Fischer KC, Slone RM, et al: Perfusion scintigraphy in the evaluation for lung volume reduction surgery: Correlation with clinical outcome. Radiology 205:243-248, 1997.
7. Jamadar DA, Kazerooni EA, Martinez FJ, et al: Semi-quantitative ventilation/perfusion scintigraphy and single-photon emission tomography for evaluation of lung volume reduction surgery candidates: Description and prediction of clinical outcome. Eur J Nucl Med 26:734-742, 1999.
8. Fukuchi K, Hayashida K, Nakanishi N, et al: Quantitative analysis of lung perfusion in patients with primary pulmonary hypertension. J Nucl Med 43:757-761, 2002.
9. Jacobstein JG: Xe-133 ventilation scanning immediately following the Tc-99m perfusion scan. J Nucl Med 15:964-968, 1974.
10. Kipper MS, Alazraki N: The feasibility of performing Xe-133 ventilation imaging following the perfusion study. Radiology 144:581-586, 1982.
11. Miron SD, Wiesen EJ, Feiglin DH, et al: Generation of parametric images during routine Tc-99m PYP inhalation/Tc-99m MAA perfusion lung scintigraphy: Technical note. Clin Nucl Med 16:501-505, 1991.
12. 43-Tc-99m: In MIRD: Radionuclide Data and Decay Schemes, DA Weber, KF Eckerman, AT Dillman, JC Ryman, eds, Society of Nuclear Medicine, New York, 1989, pp 178-179.
13. MIRD Dose Estimate Report No 10: Radiation absorbed dose from albumin microspheres labeled with Tc-99m. J Nucl Med 23:915-917, 1982.

Normal Findings

- > Wallace JM, Moser KM, Hartman MT, et al: Patterns of pulmonary perfusion scans in normal subjects. Am Rev Respir Dis 124:480-483, 1981.
- > Kosuda S, Kobayashi H, Kusano S: Change in regional pulmonary perfusion as a result of posture and lung volume assessed using technetium-99m macroaggregated albumin SPET. Eur J Nucl Med 27:529-535, 2000.
- > Feddullo PF, Kapitan KS, Brewer NS, et al: Patterns of pulmonary perfusion scans in normal subjects. IV The prevalence of abnormal scans in smokers 30 to 49 years of age. Am Rev Respir Dis 139:1155-1157, 1989.
- > Morrell NW, Roberts CM, Jones BE, et al: The anatomy of radioisotope lung scanning. J Nucl Med 33:676-683, 1992.

[Return to Table of Content](#)